



PATIENT

Roo Schrader

SPECIES

Canine

BREED

Chihuahua

SEX

Male Neutered

AGE

13 years

WEIGHT

8.75lbs

INTERPRETED BY

Maggie Machen Lamy,
DVM, DACVIM
(Cardiology)

IMAGING PERFORMED BY

Sang K Han, DVM

HOSPITAL NAME

Oso Pet Care Center

REFERRING VET

Dr. Han

INVOICE

46658

DATE

1/30/26

PRESENTING CLINICAL SIGNS

History: Recheck echo. Doing well. Grade 3/6 heart murmur.

-Current medications: Pimobendan 2.5mg 1/2-tab BID, Trifexis, Gabapentin BL

-Pertinent previous echo findings (11/2022 MML): CVD B1. Mild MR, trace TR. LA: 1.6, LA/AO: 1.3, LV: 2.3.

ECHOCARDIOGRAM FINDINGS

2D, m-mode, color flow and doppler imaging is available. Mild diffuse thickening of mitral valve leaflets with mild prolapse into the left atrial lumen. Mild eccentric mitral regurgitation with mild left atrial dilation. Normal MR velocity. Normal LV diameter with adequate myocardial function. The tricuspid valve appears normal with trace tricuspid regurgitation. Normal right atrial and ventricular diameter and morphology indicating no overt evidence of pulmonary arterial hypertension. The pulmonic and aortic valves are normal in morphology and mobility. Normal pulmonic and aortic outflow velocities with laminar flow. No obvious aortic or pulmonic insufficiency. No pericardial or pleural effusion noted. No obvious cardiac masses.

CARDIAC CHART

CANINE CARDIAC PARAMETERS	MR VMAX (m/s)	TR VMAX (m/s)	LA/AO (Boon method)	LA/AO (Heart Base; Swe)	FS (%)	EF (%)	EPSS (cm)
NORMAL PARAMETER	4.5-5.5	<2.7	1.3	<1.6	28-40	40-100	<0.6
PATIENT	5.9	NM	1.8	1.4	47	80	0.3
CANINE CARDIAC PARAMETERS	HR (BPM)	AV VMAX (m/s)	PV MAX (m/s)	BODY WEIGHT	LA 2D short axis Base view (cm)	LVIDd Avg; 2D and m-mode short axis (cm)	LVIDs Avg; 2D and m-mode short axis (cm)
NORMAL PARAMETER	50-100	0.7-1.7	0.7-1.6	BELOW	BELOW	BELOW	BELOW
PATIENT	NM	1.3	1.0	4.0	1.8	2.6	1.4
*Normal chamber parameters expressed as a mean value (SD)				3	1.27 (5.3)	2.46 (2.46)	1.36 (5.5)
BODY WEIGHT DEPENDENT PARAMETERS				5	1.40 (4.5)	2.74 (5.2)	1.60 (4.7)
*Note: All measurements based upon multi-modal images and methods. An average value is reported.				10	1.50 (3.8)	3.27 (3.5)	2.06 (3.1)
				15	1.83 (2.0)	3.71 (2.4)	2.43 (2.1)
				20	2.02 (1.9)	4.14 (2.2)	2.80 (2.0)
Adapted from June Boon, Veterinary Echocardiography, 1998				25	2.18 (2.4)	4.48 (2.9)	3.10 (2.5)
Rishniw M and Hollis NE, J Vet Intern Med 2000; 14:429-435				30	2.33 (3.3)	4.83 (3.9)	3.39 (3.4)
Hansson et al, Vet Rad and Ultrasound 2002				35	2.48 (4.3)	5.17 (5.0)	3.69 (4.5)
Bonagura et al. Echocardiography: principles of interpretation, Vet Clin North Am 15:1177, 1995				40	2.62 (5.2)	5.48 (6.1)	3.96 (5.4)
				50	2.88 (7.1)	6.07 (8.3)	4.46 (7.4)

INTERPRETATION OF THE FINDINGS & FURTHER RECOMMENDATIONS

Chronic degenerative valve disease persists with evidence of slight progression. The LA is slightly increased comparatively, which is expected given the time frame. The remainder of the study is unchanged, and no additional issues are seen.

Given these findings, typically no medications are indicated. That being said, at some point Pimobendan was instituted, which can decrease chamber sizes/ Based upon this it is likely reasonable to continue the medication. Continued assessment of progression in the future will help predict long term prognosis, which is highly variable at this stage (B1). Omega fatty acid



PATIENT

Roo Schrader

SPECIES

Canine

BREED

Chihuahua

SEX

Male Neutered

AGE

13 years

WEIGHT

8.75lbs

INTERPRETED BY

Maggie Machen Lamy,
DVM, DACVIM
(Cardiology)

IMAGING PERFORMED BY

Sang K Han, DVM

HOSPITAL NAME

Oso Pet Care Center

REFERRING VET

Dr. Han

INVOICE

46658

DATE

1/30/26

supplementation and mild salt restriction may be of some long-term benefit. Monitor for development of a cough, labored breathing, exercise intolerance or collapse episodes.

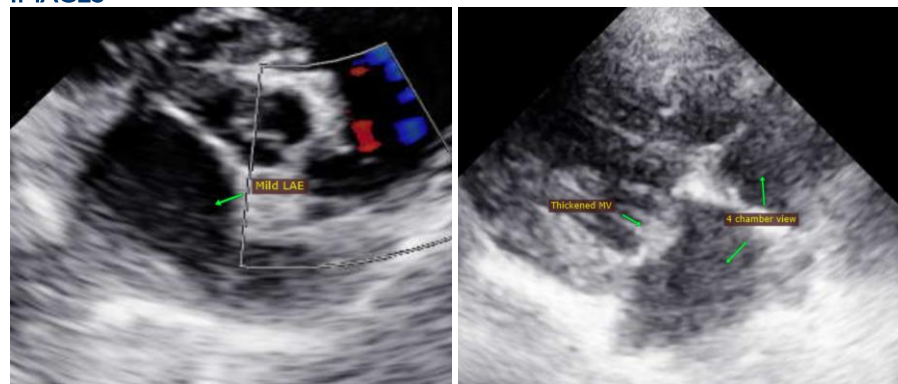
Anesthetic risk is considered mild if needed. Cardiac protective drug choices (opioid/benzodiazepine premedication, propofol or alfaxalone induction, isoflurane gas) are recommended. Pre-oxygenate for 5-10 minutes prior to induction. Monitor for arrhythmias, hypotension, and hypoxia both intra and post-operatively and intervene as necessary. Mild IV fluid restriction is recommended to avoid fluid overload. Avoid heart rate stimulating drugs such as atropine unless clinically indicated.

PLAN

Baseline BP is recommended. Continue Pimobendan 0.3mg/kg PO q12h.

Recommend conservative monitoring with a recheck echocardiogram in 6-9 months, sooner if any development of clinical signs.

IMAGES



The information and recommendations provided are based on the images presented by the referring veterinarian. No evaluation can be communicated regarding pathology that was not visible in the image/video clips provided.

Thank you for this referral. This report was generated using transcription software, and minor dictation errors may be present. If the clinical or image interpretation does not parallel your findings or if I can be of any further assistance, please contact me.

Maggie Machen Lamy, DVM
Diplomate of the American College of Veterinary Internal Medicine (Cardiology)
info@sonopath.com



PATIENT

Roo Schrader

SPECIES

Canine

BREED

Chihuahua

SEX

Male Neutered

AGE

13 years

WEIGHT

8.75lbs

INTERPRETED BY

Maggie Machen Lamy,
DVM, DACVIM
(Cardiology)

IMAGING PERFORMED BY

Sang K Han, DVM

HOSPITAL NAME

Oso Pet Care Center

REFERRING VET

Dr. Han

INVOICE

46658

DATE

1/30/26